

The Split Orbicularis Myomucosal Flap for Lower Lip Reconstruction

Yadranko Ducic, MD, FRCSC; Rhagu Athre, MD; Christopher Spencer Cochran, MD

Objectives: To describe the split orbicularis myomucosal flap and to review our center's experience with this technique for large defects of the lower lip.

Methods: All patients presenting to the senior author (Y.D.) for lower lip reconstruction using this flap were reviewed in a retrospective fashion.

Results: A total of 14 patients with a minimum follow-up of 6 months (mean, 3.4 years; range, 6 months to 5 years) underwent lower lip reconstruction using the split orbicularis myomucosal flap from May 1999 to May 2004. Twelve of the defects arose as a result of cancer resection (squamous cell carcinoma [n=8], basal cell carcinoma [n=3], and melanoma [n=1]), and 2 arose sec-

ondary to trauma. The defect crossed the vermilion in two thirds of the cases, extending for a variable distance onto the cutaneous portion of the lower lip. The defect size varied from 50% to 80% of the transverse dimension of the lower lip (mean, 68%) and involved the commissure in 4 patients. There were no flap failures, facial nerve palsies or paralyses, oral incompetence, or need for scar revision in any of our study population.

Conclusion: The split orbicularis myomucosal flap is a reliable method of reconstructing significant defects of up to 80% of the lower lip with minimal risks of microstomia or functional impairment.

Arch Facial Plast Surg. 2005;7:347-352

THE LIPS FORM THE AESTHETIC highlight of the lower one third of the face. The lips have diverse, varied roles including deglutition, articulation, expression of emotion, and most importantly, oral competence. As such, it is not surprising that lip reconstruction has been performed since at least 25 AD, when a Roman surgeon made relaxing incisions in the cheek to close a defect of the lower lip primarily.¹ Most of the modern surgical concepts regarding lip reconstruction were developed in the mid-1800s, having undergone multiple modifications since then.² However, the basic principles of lip reconstruction have not changed significantly.³⁻²⁰

The buccal and marginal divisions of the facial nerve provide the motor innervation of the lips, while sensory innervation is provided by the trigeminal nerve via its infraorbital and submental branches. The arterial supply to the lips is provided by branches of the facial artery, while the venous drainage is provided through the anterior facial vein.²¹

The primary muscle responsible for closure of the lips is the orbicularis oris. The orbicularis derives its primary innervation from the buccal branch of the sev-

enth cranial nerve. Muscle fibers of the orbicularis originate from both the intrinsic fibers of the lips themselves and partially from other muscle groups that insert onto the lips. The deep and oblique muscle fibers of the orbicularis serve to approximate the lips to the alveolar arch, while the superficial fibers serve mainly to protrude the lips away from the facial plane.²¹ The lips are primarily elevated by the levator labii superioris. The levator anguli and zygomaticus major assist with lip elevation but also draw the lips posteriorly. Depression of the lips is accomplished primarily by the combined action of the platysma, depressor labii inferioris, and depressor anguli oris. These supporting muscles of the lips are combined into 1 unit to modulate and fine tune orbicularis oris position.²¹ The buccinator is the primary muscle of the cheek. The buccinator compresses the cheek and assists in mastication. The buccinator originates off the alveolar process and pterygomandibular raphe. It inserts into the corner of each mouth deep to the other muscles of facial expression. On each side, the buccinator is composed of 3 portions: a superior portion, an inferior portion, and a middle portion. The superior and inferior portions of the buccinator merge

Author Affiliations:
Department of
Otolaryngology–Head and Neck
Surgery, University of Texas
Southwestern Medical Center,
Dallas; and Division of
Otolaryngology and Facial
Plastic Surgery, John Peter
Smith Hospital, Fort Worth,
Tex.

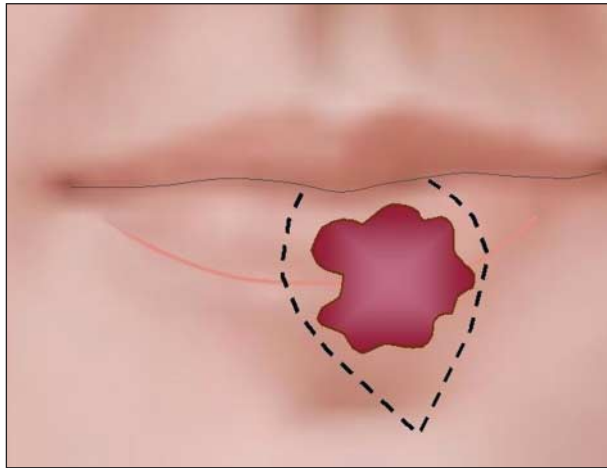


Figure 1. Proposed area of resection for a cutaneous carcinoma.

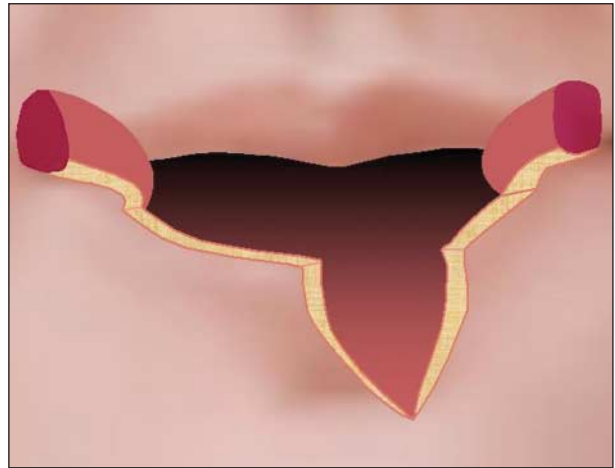


Figure 3. Split orbicularis myomucosal flaps have been raised and are ready for inset.

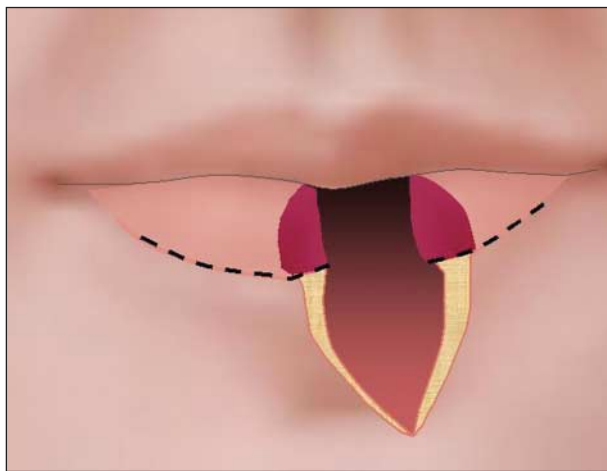


Figure 2. The defect has been created. A through-and-through incision is now created along the vermilion border bilaterally.

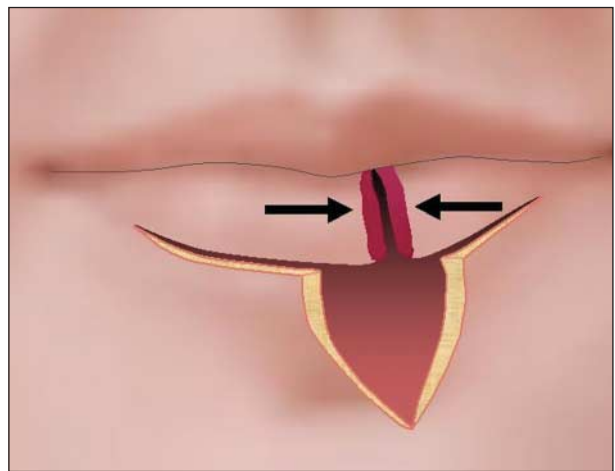


Figure 4. Flaps have been brought together by sliding them over the cutaneous portion of defect, which will be closed subsequently.

with the deep muscle fibers of the upper and lower lip, respectively. The middle portion of the buccinator travels to the angle of the mouth and then decussates. The upper fibers of the middle portion merge with the orbicularis oris fibers of the lower lip, while the lower fibers of the middle portion merge with the orbicularis fibers of the upper lip. Along with the pharyngeal constrictors, the orbicularis and buccinator form a functional ring unit. Disruption of any portion of the ring leads to lip imbalance.²¹

In this article we review our positive experience with the split orbicularis myomucosal flap for reconstruction of large defects of the lower lip.

METHODS

The basic principle of what we term *split orbicularis myomucosal flap* is that there necessarily exists more redundancy in the tissue of the red of the lip (mucosa) than of the cutaneous portion of the lip (**Figures 1-13**). The pliability of the cutaneous portion of the lip is poor relative to many other portions of the face and neck. In contrast, all adults have variable degrees of built-in redundancy of the mucosal portion of the lip (both wet and dry) that one can take advantage of in reconstruction of this area. Tra-

ditionally, whenever there existed a defect of both the cutaneous and mucosal portions of the lip, they were usually reconstructed with composite flaps containing both of these structures that were “borrowed” from adjacent areas of the lip or upper lip. This would necessarily result in significant microstomia for any significant defects. Alternatively, regional cutaneous tissue could be recruited into the area. However, this tissue would not contain neurologically intact orbicularis muscle and would thus give a poor functional result. The split orbicularis myomucosal flap maintains the innervation to the lower lip with similar immediately adjacent tissue, while minimizing loss of transverse dimension and risk of microstomia.

The defect is first critically analyzed to determine which method of reconstruction would be ideally suited. There must be at least 20% of the lower lip mucosa and underlying orbicularis muscle remaining in aggregate, either unilaterally or bilaterally, to assure a good aesthetic and functional outcome. Prior to infiltration of local anesthetic, the vermilion border is marked. Following infiltration of 1% lidocaine hydrochloride with 1:100 000 epinephrine solution, an incision is made along the vermilion to the level of the oral commissure bilaterally. If required (as in commissure defects or younger patients with decreased mucosal laxity), this incision is carried along the vermilion into the upper lip for a variable distance. The incision is then completed through the orbicularis oris muscle and the oral mucosa, creating a laterally pedicled vascularized myomu-

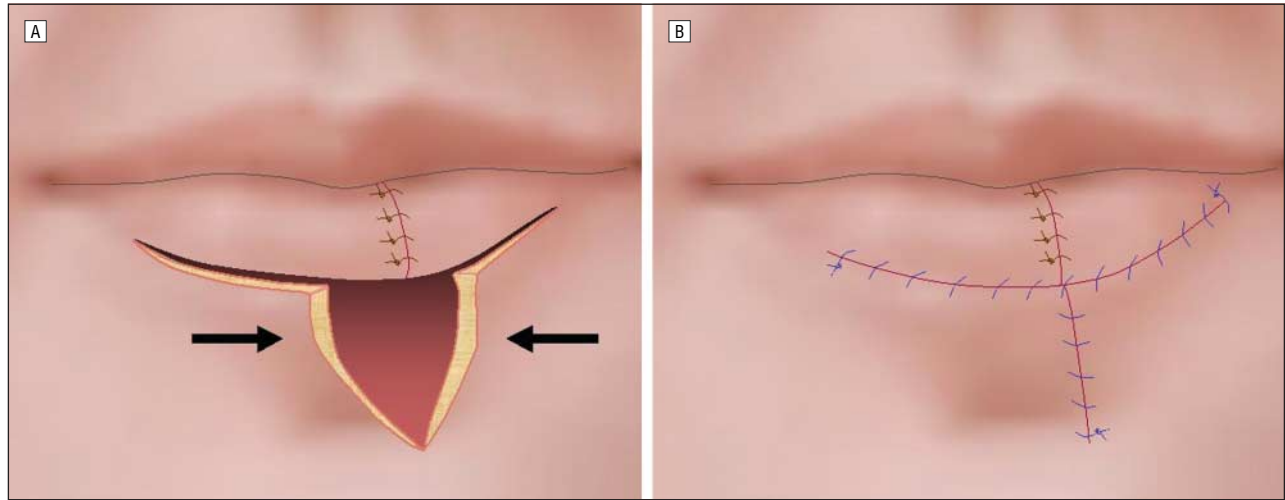


Figure 5. Final closure.

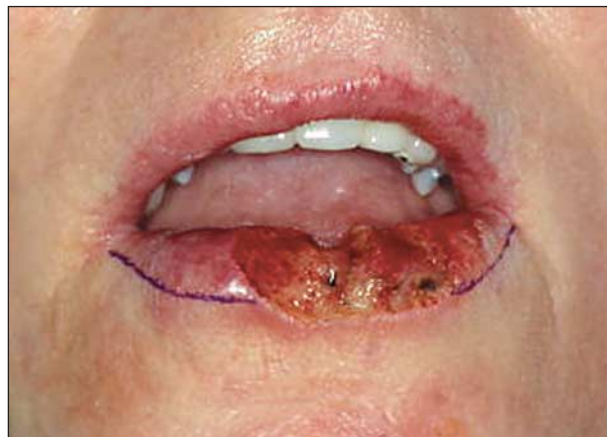

Figure 6. A 50% defect of the lower lip in a female patient following Mohs' excision of squamous cell carcinoma. Proposed incision along the vermilion has been made.

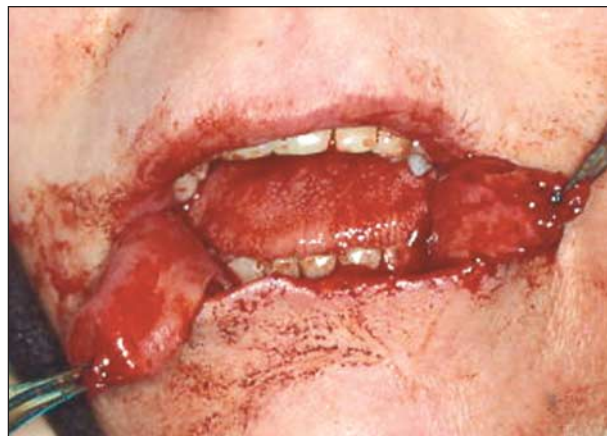

Figure 7. Split orbicularis myomucosal flaps have been harvested (patient from Figure 6). Note the through-and-through harvest along the vermilion.

cosal flap that incorporates the wet and dry lip mucosa and intervening muscle. If the flap is harvested onto the upper lip, all the steps are identical except for the need to identify, skeletonize, and preserve the neurovascular bundle at the level of the commissure. Otherwise, the through-and-through cut is continued onto the upper lip. The orbicularis muscle is then re-

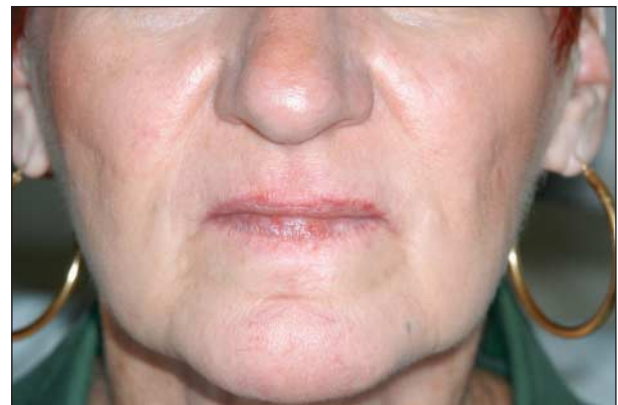

Figure 8. Result (patient from Figure 6) at approximately 3 years. Note the lack of microstomia.

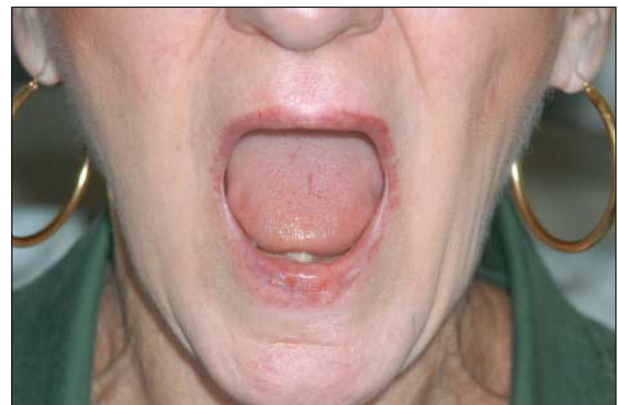

Figure 9. Same patient as in Figures 6 through 8 at approximately 3-year follow-up with reasonable functional outcome.

approximated with resorbable sutures. The vermilion is precisely trimmed and aligned with a temporary nonresorbable nylon suture followed by mucosal approximation both introrally and externally. Any associated cutaneous defect is simply reapproximated in a vertical fashion with "traditional" techniques. The separation of the cutaneous from the mucosal portions of the flap reconstruction results in significant improvements in the transverse dimension of the lip and functional outcome.

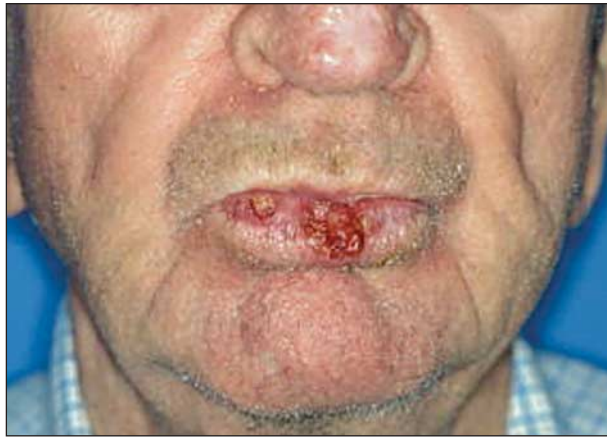

Figure 10. Preoperative view of patient with invasive squamous cell carcinoma of the lower lip.

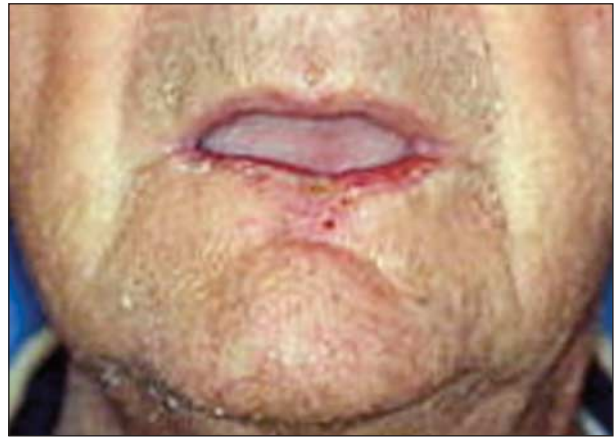

Figure 13. Postoperative result of the patient in Figures 10 and 11 at 3 months with moderate mouth opening.

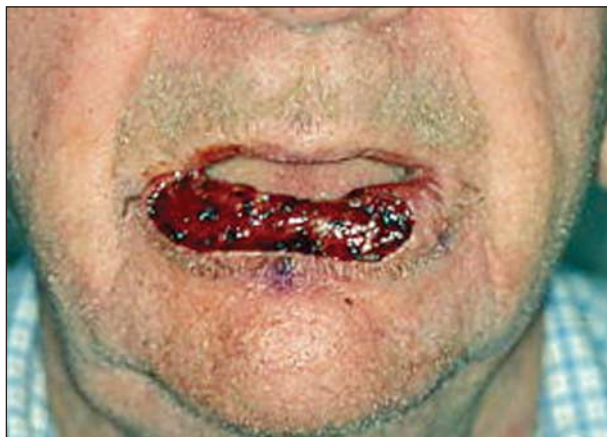

Figure 11. Approximately 80% defect of lower lip following Mohs' excision of the patient's carcinoma in Figure 10. Here, it was necessary to take the flap harvest onto the upper lip bilaterally.

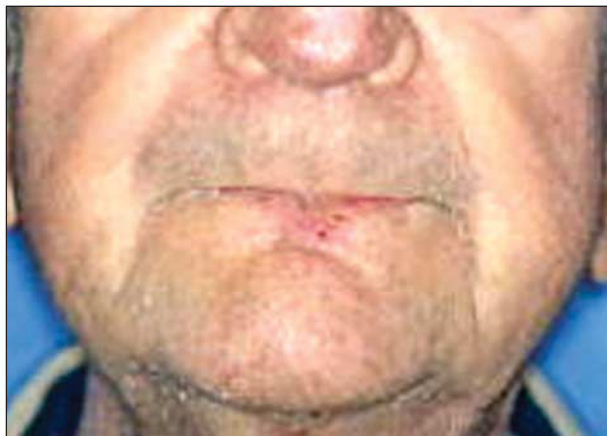

Figure 12. Postoperative result on rest at 3-month follow-up from the patient in Figures 10 and 11.

All patients are kept on a liquid diet for 1 week postoperatively, followed by resumption of normal intake thereafter. Dentures, if worn, are not allowed for a period of 2 weeks following the procedure.

RESULTS

A retrospective review of all lower lip reconstructions performed by the senior author (Y.D.) using the split orbicularis myomucosal flap from May 1999 to May 2004 was performed. Fourteen patients underwent lip reconstruction using this flap during the study period, with a minimum follow-up of 6 months (mean, 3.4 years; range, 6 months to 5 years). There were 9 men and 5 women (mean age, 57 years; range, 41-77 years). Twelve of the defects arose as a result of cancer resection (squamous cell carcinoma [n=8], basal cell carcinoma [n=3], and melanoma [n=1]), and 2 arose secondary to trauma. The defect crossed the vermilion in two thirds of the cases, extending for a variable distance onto the cutaneous portion of the lower lip. The defect size varied from 50% to 80% of the transverse dimension of the lower lip (mean, 68%) and involved the commissure in 4 patients. There were no flap failures, facial nerve palsies or paralyzes, oral incompetence, or need for scar revision in any of our study population. All patients were tolerating their pre-morbid diet (with denture placement if required). All patients undergoing reconstruction of defects crossing the commissure underwent a secondary formal planned commissuroplasty to maximize the angulation normally noted at this level.

COMMENT

The choices regarding lip reconstruction are plentiful and include the remaining lip segment, the opposite lip using a cross-lip flap technique, the adjacent cheek and nasolabial area, the submental and chin area, and distant flaps including free flaps.²² These options are organized in order of decreasing preference. Functional goals for lip reconstruction include vermilion coverage, skin coverage, reapproximation of the commissure, maintenance of adequate stomal diameter for normal mouth opening and possible dentures, recreation of the oral sulcus, recreation of a competent oral sphincter, perioral sensation, and cosmesis.²²

Primary repair of lower lip defects is possible for small defects. Up to 25% of the upper lip and 33% of the lower lip can be repaired via direct approximation and primary closure. This can all be done with minimal cosmetic and functional disturbance.¹ Defects ranging from 30% to 65% of the lip require an alternative method of reconstruction, most commonly a cross-lip technique.^{1,23} The first recorded cross-lip flap was performed by Pietro Sabattini of Innola, Italy.¹ Sabattini transferred a vermilion-bordered flap from the lower lip to reconstruct an upper lip defect. Sophus August Vilhelm Stein of Copenhagen, Denmark, described bilateral upper central lip flaps for reconstruction of a lower lip defect 10 years following Sabattini. Gordon Buck, during the Civil War, was the first surgeon in the English-speaking world to describe a cross-lip reconstruction.²⁴ Despite these reports of cross-lip reconstruction, it was not until Robert Abbe published his method for cross-lip reconstruction in 1898 that the medical community took notice of the procedure.

The Abbe flap and its modifications can be used to reconstruct medial or lateral lip defects. Traditionally, the Abbe flap is designed to have a width equal to one-half the length of the lip defect. The Abbe flap is a triangularly shaped flap with its base on the vermilion of the opposite lip of the defect. The width of the base is 50% of the length of the lip defect. The flap is rotated 180° on a pedicle and sutured to the lip defect. The donor site is closed primarily.²⁵ V-Y advancement flaps can be used to advance buccal mucosa for mucosal lining or extra vermilion if needed. Medial defects of the lower lip are repaired with Abbe flaps bordering the philtrum so that closing the donor site will leave a scar on the philtral ridge for maximum camouflaging of the scar. The Ashley modification of the Abbe flap used a skin flap based on the commissure and tangential to the vermilion of the opposite lip.²⁶ The freed medial portion of vermilion is rotated 180° to become the vermilion of the opposite lip, and an island of vermilion forming the commissure is created laterally. As a second-stage operation, the flaps are incised and the commissure is recreated.

Estlander flaps are named for Jakob August Estlander of Finland, who first described the flap in 1872. These flaps essentially are Abbe flaps for the commissure. Estlander originally rotated a lateral upper lip flap around the commissure to reconstruct a lateral lower lip defect.²⁷ Secondary revision is necessary to recreate the sharp angle of the commissure. The modified Estlander flap is based slightly more medially to avoid damaging the commissure, though secondary incision of the flap is still necessary.²⁵ More medial defects of the lip can be repaired by transposing tissue from the lateral portion of the same lip and repairing the lateral defect with an Estlander flap.

Estlander and Abbe flaps represent 2 types of cross-lip flaps. Smith²⁵ stated that lateral defects should be repaired with Estlander flaps whereas medial defects should be repaired with Abbe flaps. Smith performed a study to determine the physiologic changes following cross-lip flaps. Smith managed to show a return of normal electromyographic tracings 1 year following surgery and estimated that there was only a 60% to 70% return of nor-

mal muscle function.²⁵ The problem encountered with both the Abbe and Estlander flaps is the pin cushioning that invariably results at the recipient site as well as significant aesthetic consequences at the donor site. In addition, larger defects may have some incompetency owing to disruption of the motor supply to the orbicularis muscle that is included in the flap.

The step method may also be used for defects of up to 66% of the lower lip. In larger lesions, the step technique can be used in conjunction with the Estlander or fan flap. The step technique involves the excision of 2 to 4 small squares arranged in a stair-step fashion on a 45° axis from medial to lateral. This provides for adequate laxity of skin and subcutaneous tissue to close the defect. The horizontal component of each step measures approximately one-half the length of the defect. Hence, 2 to 4 steps are usually required to close the defect. The vertical dimension of each step is approximately 8 to 10 mm.²⁸ In lesions that are located more laterally in the lip, the steps are arranged asymmetrically with shorter horizontal segments on the lateral side of the defect. Multiple conspicuous scars will result from even the proper use of this technique.

Defects larger than 65% are amenable to reconstruction with the Karapandzic flap or fan flap, both of which marry the orbicularis muscle to the cutaneous portion of the flap that will be used for lip reconstruction. The upper limit of defect length amenable to treatment via these techniques is approximately 80% of the total lip length. The fan flap is similar to the Estlander flap in that it revolves rotation of tissue around the commissure.²⁹ The fan flap, however, includes more tissue from the nasolabial area and is indicated for total or near-total defects of the lower lip.²⁹ Rotation of the large fan-shaped flap provides for a new commissure and maintains the integrity of a portion of the oral sphincter. Preservation of this portion of the sphincter allows the possibility of return of function through neurotization despite the fact that the flap has been denervated during surgery. The problem with this flap is the significant microstomia and vermilion deficiency that can be expected. Functionality is, however, maintained. Gillies and Millard²⁹ documented the eventual return of oral competence in their series of long-term follow-ups, and Rea et al³⁰ obtained electromyographic evidence of nerve regeneration.

Karapandzic³¹ modified the fan flap in 1974, maintaining a neurovascular pedicle. Curvilinear incisions are made circumorally, extending along the nasolabial crease of one side of the face, through the crease above the chin to the nasolabial crease on the contralateral side. The lower lip defect is closed primarily owing to the laxity created by the aforementioned incisions.³¹ Sphincter continuity is restored and motor function, as well as sensation, is never interrupted. The primary disadvantage in this technique is microstomia, which may require subsequent commissurotomy in 25% of cases. Reconstruction of lateral lip defects using this method can result in commissure asymmetry. Jabaley and colleagues²¹ described their experiences with the Karapandzic flap.²¹ The primary shortcomings of the Karapandzic flap in their experience included underprojection of the lower lip, tightness of the lower lip, and microstomia that is invariably seen with this flap.

Total lip defects and defects larger than 80% of lip length would be candidates for reconstruction via larger composite flaps, cheek flaps, or possible free-tissue transfer flaps.¹ The Burow method represents the most common cheek advancement method for repair of complete lower lip defects. Von Burow, in 1838, excised 4 full-thickness triangles, all with their bases at the level of the commissures. Von Burow did not publish his idea until 1855,¹ while Bernard³² performed the same technique in 1853.

Bernard and Von Burow described a procedure that transposed full-thickness triangular flap to reconstruct the upper or lower lip. The vermilion was reconstructed using a mucosal advancement flap and everting the mucosa to reconstruct vermilion. Multiple authors have made modifications on the Burow technique, though the substance of the technique has changed little.³² This flap can be used to reconstruct total lip defects with minimal microstomia risk. However, as no functional orbicularis is included in this method, the lip is adynamic and poorly functional. Regional flaps and free-tissue transfers have also been described for use in total and subtotal lip defects.^{1,29,33}

The ideal flap would have maintenance of lip volume, function, and aesthetics with no donor site morbidity. We believe that the split orbicularis myomucosal flap fulfills these goals in properly selected patients with defects of the lower lip involving up to 80% of its dimension. Essentially, the vertical lines of the lip may be thought of as representing a bank of mucosal tissue that is recruited in this flap to minimize the risk of microstomia. The orbicularis, although transversely split, has maintenance of its functional integrity due to preservation of its laterally based motor supply. It has been used primarily for combination defects of the lower lip to include mucosa, muscle, and skin. Lip volume and aesthetics are maintained owing to the recruitment of very similar adjacent lip tissue. The incision is easily hidden within the vermilion itself. The flap is easy to harvest, reliable, and associated with favorable long-term outcomes. We encountered no significant problems with either the harvest or healing of this flap in our study group.

CONCLUSIONS

We describe the utility and technique of the split orbicularis myomucosal flap for major lower lip reconstruction. The flap is simple to harvest, and this method maintains the function of the orbicularis and does not result in significant transverse shortening of the lip. It should be considered for reconstruction of defects of the lower lip up to 80%.

Accepted for Publication: November 16, 2004.

Correspondence: Yadranko Ducic, MD, FRCSC, Division of Otolaryngology and Facial Plastic Surgery, John Peter Smith Hospital, 1500 S Main St, Fort Worth, TX 76104 (yducic@sbcglobal.net).

REFERENCES

- Mazzola RF, Lupo G. Evolving concepts in lip reconstruction. *Clin Plast Surg*. 1984;11:583-617.
- Webster RC, Coffey RJ, Kelleher RE. Total and partial reconstruction of the lower lip with innervated muscle-bearing flaps. *Plast Reconstr Surg*. 1960;25:360-371.
- Abbe R. A new plastic operation for the relief of deformity due to double harelip. *Medical Records*. 1898;53:477.
- Bradley C, Leake JE. Compensatory reconstruction of the lips and mouth after major tissue loss. *Clin Plast Surg*. 1984;11:637-653.
- Cosman B, Gon K, Crikelair GF. Horizontal cross-lip flap with pedicle at commissure: a case report. *Plast Reconstr Surg*. 1968;41:273-275.
- Davis JS. *Plastic Surgery: Its Principles and Practice*. Philadelphia, Pa: Blakiston's Son & Co; 1919.
- Flanagin WS. Free composite grafts from lower to upper lip. *Plast Reconstr Surg*. 1956;17:376-380.
- Goldstein MH. The elastic flap for lip repair. *Plast Reconstr Surg*. 1990;85:446-452.
- Jabaley ME, Clement RL, Orcutt TW. Myocutaneous flaps in lip reconstruction: applications of the Karapandzic principle. *Plast Reconstr Surg*. 1977;59:680-688.
- Kawamoto HK. Correction of major defects of the vermilion with a cross-lip vermilion flap. *Plast Reconstr Surg*. 1979;64:315-318.
- Luce EA. Reconstruction of the lower lip. *Clin Plast Surg*. 1995;22:109-121.
- Martin HE. Cheiloplasty for advanced carcinoma of the lip. *Surg Gynecol Obstet*. 1932;54:914-916.
- McGregor IA. Reconstruction of the lower lip. *Br J Plast Surg*. 1983;36:40-47.
- Millard DR, McLaughlin CA. Abbe flap on mucosal pedicle. *Ann Plast Surg*. 1979;3:544-548.
- Moore FT, Lendvay PG. Free composite lip-switch procedure. *Br J Plast Surg*. 1969;22:262-264.
- Owens N. A compound neck pedicle designed for the repair of massive facial defects: formation, development, and application. *Plast Reconstr Surg*. 1955;15:369-389.
- Templer J, Renner G, Davis WE, Thomas JR. "How I do it"—plastic surgery: practical suggestions on facial plastic surgery: a modification of the Abbe-Estlander flap for defects of the lower lip. *Laryngoscope*. 1981;91:153-156.
- Tobin GR, O'Daniel TG. Lip reconstruction with motor and sensory innervated composite flaps. *Clin Plast Surg*. 1990;17:623-632.
- Walker JC, Sawhney OP. Free composite lip grafts. *Plast Reconstr Surg*. 1972;50:142-146.
- Zide BM. Deformities of the lips and cheeks. In: McCarthy JG, ed. *Plastic Surgery*. Vol 3. Philadelphia, Pa: WB Saunders; 1990:2009-2056.
- Jabaley ME, Orcutt TW, Clement RL. Applications of Karapandzic principle of lip reconstruction after excision of lip cancer. *Am J Surg*. 1976;132:529-532.
- Wilson JSP, Walker EP. Reconstruction of the lower lip. *Head Neck Surg*. 1981;4:29-44.
- Hagerty RF, Hagerty RC, Hagerty HF. Reconstruction of full thickness lip defects. *South Med J*. 1987;80:1094-1096.
- Buck G. History of a case in which a series of plastic operations was successfully performed for the restoration of the right half of the upper lip and adjacent portions of the cheek and nose. In: *Transcripts of the Medical Society of the State of New York*. Lake Success: Medical Society of the State of New York; 1864:173-186.
- Smith JW. The anatomical and physiological acclimatization of tissue transplanted by the lip switch technique. *Plast Reconstr Surg*. 1960;26:40-56.
- Ashley FL. Reconstruction of the lower lip. *Plast Reconstr Surg*. 1955;15:313-327.
- Estlander JA. A method of reconstructing loss of substance in one lip from the other lip [reprinted in *Plast Reconstr Surg*. 1968;42:361]. *Arch Klin Chir*. 1872;14:622.
- Johanson B, Aspelund E, Breine U, Holmstrom H. Surgical treatment of non-traumatic lower lip lesions with special reference to the step technique: a follow-up on 149 patients. *Scand J Plast Reconstr Surg*. 1974;8:232-240.
- Gillies HD, Millard DR. *Principles and Art of Plastic Surgery*. Boston, Mass: Little Brown & Co Inc; 1957.
- Rea JL, Davis WE, Rittenhouse LK. Reinnervation of an Abbe-Estlander and a Gillies fan flap of the lower lip: electromyographic comparison. *Arch Otolaryngol*. 1978;104:294-295.
- Karapandzic M. Reconstruction of lip defects by local arterial flaps. *Br J Plast Surg*. 1974;27:93-97.
- Bernard C. Cancer de la levre inferieure opere par un procede nouveau. *Bull Mem Soc Chir Paris*. 1853;3:357-362.
- Owens N. Simplified method of rotating skin and mucous membrane flaps for complete reconstruction of the lower lip. *Surgery*. 1944;15:196-200.